

Back Pain Syndromes: Causes, Symptoms, Importance of Differential diagnosis and Advises of Therapy

Karski Tomasz^{1*}, Karski Jacek², Karska Klaudia³ and Kulka Małgorzata⁴

¹Vincent Pol University in Lublin, Poland

²Pediatric Orthopedic and Rehabilitation Department of Medical University, Lublin, Poland

³Department of Radiology, Medical University, Lublin, Poland

⁴Department of Neurology, Medical University, Lublin, Poland

*Corresponding author: Karski Tomasz, Professor Lecturer, Vincent Pol University, Lublin, Poland, E-mail: tmkarski@gmail.com

Received date: April 10, 2020; Accepted date: April 24, 2020; Published date: May 01, 2020

Copyright: © 2020 Tomasz K, et al. This is an open-access article distributed under the terms of the Creative Commons Attribution License, which permits unrestricted use, distribution, and reproduction in any medium, provided the original author and source are credited.

ABSTRACT

The back pain is a frequent problem of patients in orthopedics, neurology and other departments. In our opinion-the causes of the pain are connected with various illnesses or anatomical disorders of the spine such as hiperlordosis of lumbar spine, or scoliosis.

There are also other causes of back pain like spondylolisis, spodylolithesis, prolapsed nucleus pulpous, oncology symptoms but in the article, we focus on the causes of special types of scoliosis and group of patients with “hiperlordosis of lumbar spine” as the causes of “back pain syndromes.” In our research we found that etiology of scoliosis is connected with biomechanical factors- “permanent standing ‘at ease’ on the right leg” and walking/gait, which is described in next chapters.

Key words: Back pain; Scoliosis; Symptoms; Therapy; Prophylaxis

INTRODUCTION

Information about etiology of the so-called idiopathic scoliosis. (Adolescent Idiopathic Scoliosis (AIS))[1-42] (Figures 1-3) and about “back pain.” In the years 1984-1995, in examination of many children- in 2020 the total number of patients has reached 2500, it was found that “idiopathic scoliosis” is connected with the asymmetrical movement of hips and next with function-permanent “standing ‘at ease’ on the right leg” and “gait.” The limitation of adduction of the right hip, or even abduction contracture of this joint 5 to 10 degree is one of the symptoms of “The Syndrome of Contractures and Deformities” [SofCD] according to Prof. Hans Mau from Tübingen, Germany [35,36] and Lublin observations [8-31]. In the diagnosis, the checking of hips movement is crucial. The examination of hips movement should be in the straight position of these joints-and it is similar to the “standing position” or to the “stance phase in walking.” The etiology of scoliosis is strictly biomechanical and development of spine deformity is through function-“standing” and “gait” (Figures 1-3). The standing on the right leg is permanent and once started at the age of two, lasts throughout the lifetime. So, the “cumulative time” of standing on the right leg is the cause of scoliosis and in adults the cause of “spine pain syndromes” (Figures4, 5a, 5b, 6a, 6b) and in many cases of “arthrosis of the right hip” [21, 23, 25, 30].

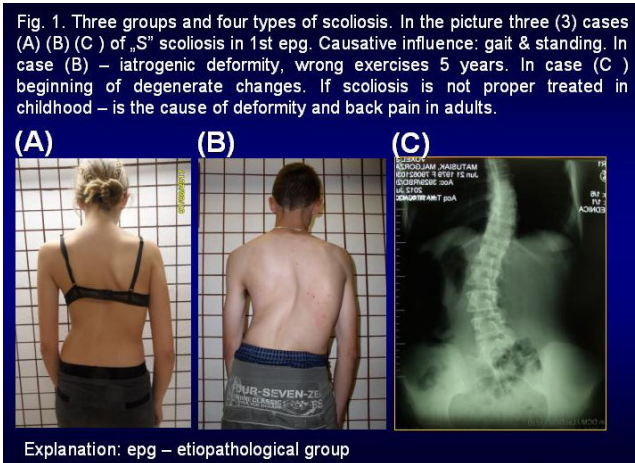


Figure1: Three groups and four types of scoliosis. In the picture three (3) cases (A) (B) (C) of “S” scoliosis in 1st epg. Causative influence: gait & standing. In case (B)-iatrogenic deformity, wrong exercises 5 years. In case (C) beginning of degenerate changes. If scoliosis is not proper treated in childhood -is the cause of deformity and back pain in adults.

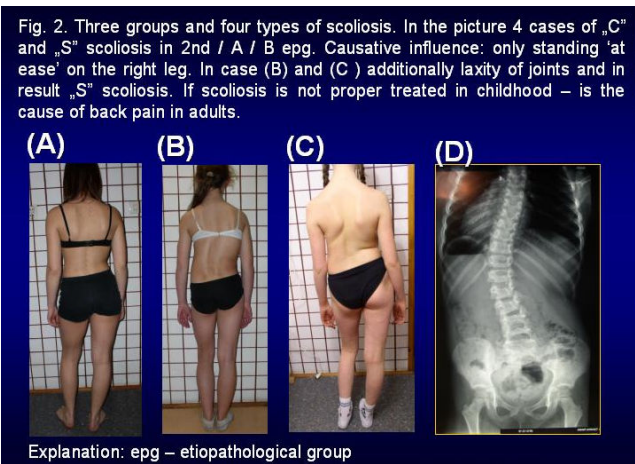


Fig. 2. Three groups and four types of scoliosis. In the picture 4 cases of “C” and “S” scoliosis in 2nd / A / B epg. Causative influence: only standing ‘at ease’ on the right leg. In case (B) and (C) additionally laxity of joints and in result “S” scoliosis. If scoliosis is not proper treated in childhood – is the cause of back pain in adults.

Figure 2: Three groups and four types of scoliosis. In the picture 4 cases of “C” and “S” scoliosis in 2nd/A/B epg. Causative influence: only standing ‘at ease’ on the right leg. In case (B) and (C) additionally laxity of joints and in result “S” scoliosis. If scoliosis is not proper treated in childhood-is the cause of back pain in adults.

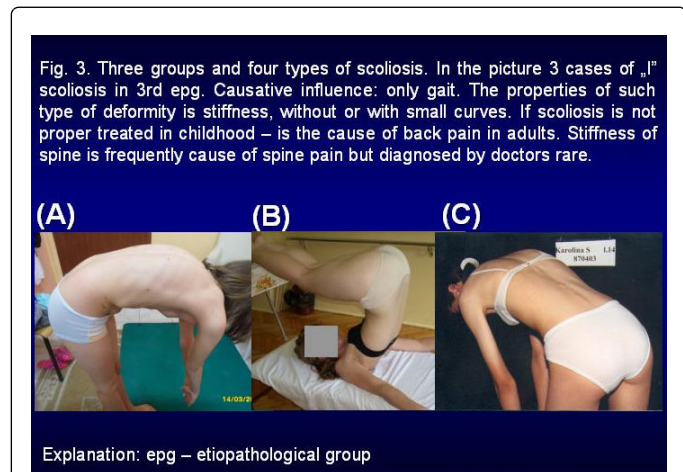


Figure 3: Three groups and four types of scoliosis. In the picture 3 cases of “I” scoliosis in 3rd epg. Causative influence: only gait. The properties of such type of deformity is stiffness, without or with small curves. If scoliosis is not proper treated in childhood-is the cause of back pain in adults. Stiffness of spine is frequently cause of spine pain but diagnosed by doctors rare.

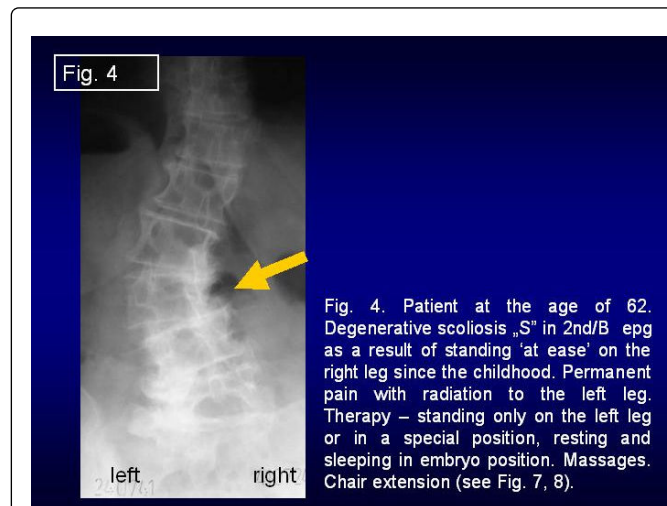


Figure 4: Patient at the age of 62. Degenerative scoliosis “S” in 2nd/B epg as a result of standing ‘at ease’ on the right leg since the childhood. Permanent pain with radiation to the left leg. Therapy-standing only on the left leg or in a special position, resting and sleeping in embryo position. Massages. Chair extension (see Figure 7).

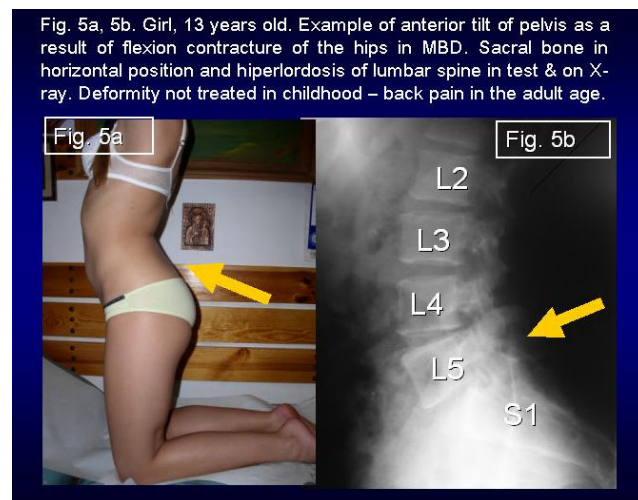


Figure 5: (a,b) Girl, 13 years old. Example of anterior tilt of pelvis as a result of flexion contracture of the hips. Sacral bone in horizontal position, hiperlordosis of lumbar spine in clinical test & on X-ray. Deformity not treated in childhood-back pain in adult age.

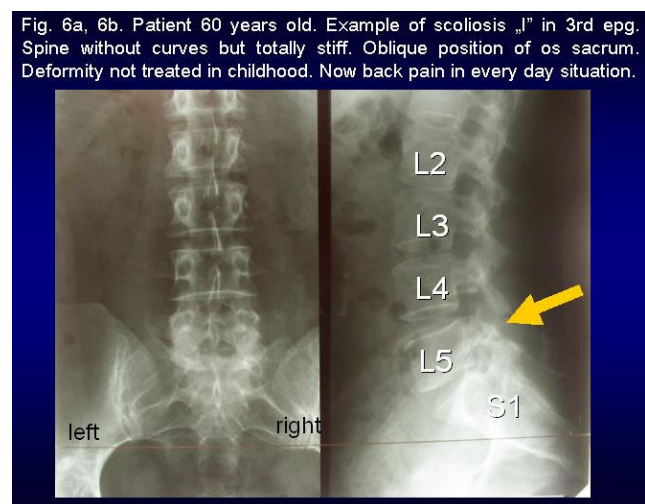


Figure 6: (a,b) Patient 60 years old. Example of scoliosis “I” in 3rd epg. Spine without curves but totally stiff. Oblique position of os sacrum. Deformity not treated in childhood. Now back pain in every day situation.

Additional causes in development of scoliosis in children and back pain syndromes in adults [19,22-25]. In many children or adults with scoliosis we can see “neurological symptoms” and there are typical for the Minimal Brain Dysfunctions (MBD). These neurological disorders are mostly caused by complicated or pathological pregnancies and problems in delivery. During examination of children and adults suffering from scoliosis and back pain such anamnesis was constantly presented. The neurological disorders are:

Anterior tilt of pelvis and hiperlordosis of lumbar spine (Figures 5a and 5b), because of flexion contracture of hips flexors. In such

situation the stability between pelvis and spine is diminished-it enables an easy development of scoliosis and next back pain,

Extension contracture of the trunk's muscles as typical symptom of MBD-here we should remember that in "S" scoliosis in 1st epg group/type and in "I" scoliosis in 3rd epg group/type-the spine is stiff in "extension position" and this symptom is typical for all scoliosis patients (Figures 6a and 6b). Stiffness of spine is one of many causes of back pains.

Laxity of joints-facilitates the development of scoliosis and is an important cause of back pain.

New classification of so-called idiopathic scoliosis [8-30,42] (Figures 1-3).

The type of spine deformity is connected with "model of hips movement" and etiological factors-"gait" and "standing 'at ease' on the right leg."

Scoliosis 3D-"S" 1st etiopathological group (epg)-double curve. Stiff spine. Rib hump on the right side of the thorax. Connection with "gait" and permanent "standing 'at ease' on the right leg." Mostly-rapid progression. This type of scoliosis "as example of the spine deformity" is described in orthopedic articles and in Internet.

Scoliosis 1D or 2D-"C" 2nd/A epg-one curve-lumbar left convex. Connected with permanent standing at ease on the right leg. In many orthopedic articles this type of scoliosis is mostly described "as paresis/paretial scoliosis."

Scoliosis 2D or 3D "S" 2nd/B epg-two curves. Connection with permanent standing 'at ease' on the right leg and additionally with laxity of joints or/and previous, harmful exercises. In older people the standing on the right leg is the cause of degenerative scoliosis and heavy back pain syndrome (Figure 4).

Scoliosis 2D or 3D-"I" 3rd epg Deformity has the form of a stiff spine. No curves or small ones. The only cause is gait. Clinical symptoms are "stiffness of the spine in children" and "pain syndromes in adults (Figure 6a and 6b). Till 2004 this type of spine deformity was not described as "scoliosis."

Problems of back pain in context of scoliosis on material from 1984.

In our orthopedic experience -the problem of back pain is connected mostly with abnormalities of spine anatomy-therefore we describe in article two causes-hiperlordosis of lumbar spine and scoliosis "C" and "S" in 2ndetiopathological group and type (epg) in Lublin classification. Back pain syndrome can appear also if the spine is stiff. Such symptoms are typical for "I" scoliosis in 3rd epg group/type in new Lublin classification. Other causes are connected with the anatomical anomalies such as spondylolisis and spondylolisthesis. Since 1984 we have gathered a material containing 2500 patients, adults but also young people treated in Pediatric Orthopedic and Rehabilitation Department in Medical University in Lublin, Poland in years 1995-2009 (in these years Prof. T. Karski was the Head if the Department). In all orthopedic, neurology or another departments in many hospitals we should remember about necessity of differential diagnosis-the "back pain syndromes" can be connected with above described "orthopedic spine disorders"-scoliosis or only stiffness of spine and not as the symptoms of neurology or oncology diseases.

Proper therapy of scoliosis and back pain. In the first plan-is very important to make proper, differential diagnosis to determinate "the causes of illness and correct diagnosis". In therapy of scoliosis in children-flexion stretching exercises for hips are very important-

especially for right hip, for spine to cure the "contracture"-shortenings of soft tissues-muscles, fascias, tendons, capsules of the hips and spine joints. The aim of such therapy is-obtaining full, symmetrical movement of hips and spine what is essential for a correct development of spine. All these exercises are similar or the same as the ones in karate, taekwondo, aikido, kung fu or yoga. Here I would like to inform that flexion exercises in the treatment of scoliosis in Poland (1960-1970) were introduced by Prof. Stefan Malawski from Warsaw/Otwock[31-34] and with T. Karski personal discussions). Such early therapy in children we can see as "important prophylaxis program against "syndrome of back pain" in adults.

For patients with back pain we advise the resting and sleeping in embryo position, chair extension (Figures 7 and 8) to relieve the neuro-roots, exercises in warm water-especially in geothermal water and of course, in serious cases, adequate analgesics. It is extremely important to avoid standing on the right leg by all neurological and other patients groups. In many cases standing on the left or in special "therapeutically position" in abduction 20-30 degree and in internal rotation 20 degree is very beneficial, at once diminishing the pain.

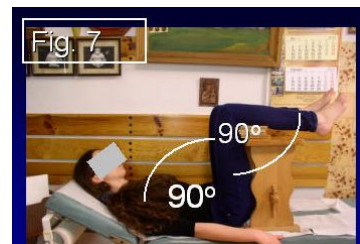


Figure 7: Patient 22 year old. Anterior tilt of pelvis. Scoliosis "C" (2/A epg). Spondylolisthesis L5-S1. Pain with radiation to the left leg.




Figure 8: Patient 60 year old. Scoliosis lumbar left convex-in new classification-"C" scoliosis 2nd epg. Back pain syndrome from 10 years

Treatment: Chair extension for the spine. The methods of therapy author (T. Karski) learned in Germany in 1968 in Orthopedic Department in Leipzig (in German: Perlsches Brett Behandlung). The extension therapy needs long time be realized-many days or weeks. Additionally exercises in geothermal water and special method of standing - in abduction and internal rotation.

Discussion to the problem of scoliosis and back pain

All old conceptions of etiology of “idiopathic scoliosis” [1, 2, 31, 37-41] were never confirmed. The etiology of idiopathic scoliosis which deformity we called now “So-called Idiopathic Scoliosis” was described in 1995-2007.

In our opinion the “back pain syndromes” occur in the following cases and in scoliosis cases particularly:

Hiperlordosis of lumbar spine-because of “pressure syndromes” to nerve roots,

Scoliosis in the new classification “C” and “S” in 2ndA/B group-because of “presses on nerve roots” on concave site of curve or because of pulling on nerve root on convex side of spine,

Stiffness of the spine-in scoliosis “I” in 3 rd group in the new classification, because of “lots of movement of spine,”

Spondylolisthesis,

Back pain can be also as a symptom of various neurological or other illnesses.

Here I would like to explain that the cause of pain is situated in many places in the spine and surgery in such situation is not a proper method of therapy. According to our opinion-the proper method of treatment is only physiotherapy. Here I would like to repeat our explanation-the cause of pain is situated in many levels of the spine. As surgery concentrates on one or two levels of the spine it cannot cure the spine pain as a whole. In our praxis we have observed that physiotherapy is good in 30%of our patients, is excellent in 20% and sufficient in 50% of cases.

Conclusions

The back pain syndromes are mostly connected with the pathological changes in the anatomy of the spine deformity of axis, changes of “intervertebral joints” and shortenings (contractures) of the soft tissues-ligaments, capsules, fascias, muscles of the spine.

The changed axis and disorders in the anatomy of spine are caused mostly by so-called Idiopathic Scoliosis. There are three groups and four types of this deformity.

The main causes of back pain are mostly:

Hiperlordosis of lumbar spine-in patients with primary MBD,

The “C” and “S” scoliosis in 2nd/A/B epg-in adults in form of degenerative spine deformity.

Stiffness of the spine in “I” 3 rdepg type of scoliosis-frequent spine pain cause but rare diagnosed till now.

Congenital or acquirer malformation of the spine like spondylolisthesis, congenital scoliosis, spine deformity in context of thorax deformity.

All cases of “back pain” need the precise differential diagnosis to explain the causes of the illness.

In prophylaxis of back pain in adults it is important to introduce to all children the rules of causal prophylaxis against scoliosis (see chapter above).

In therapy of back pain-on the first plan is:

To avoid the standing ‘at ease’ on the right leg,

Rest and sleep in embryo position,

In heavy cases “chair extension” and in the “pain-free phase” of the illness-exercises in geothermal water.

Physiotherapy-regularly at home and in rehabilitations centers.

Surgery in back pain syndromes is necessary only in very rare cases resistant to conservative treatment.

Acknowledgment

I would like to express my many thanks to Miss Honorata Menet for correction of the article

References

1. Burwell G, Dangerfield PH, Lowe T, Margulies J (2000) Spine. Etiology of Adolescent Idiopathic Scoliosis: Current Trends and Relevance to New Treatment Approaches. Philadelphia 14(2):324.
2. Dangerfield PH, Dorgan JC, Scutt D, Gikas G, Taylor JF (1995) Stature in Adolescent Idiopathic Scoliosis (AIS).14 Meeting EPOS, Brussels,pp:210.
3. Green NE, Griffin PP. (1982) Hip dysplasia associated with abduction contracture of the contralateral hip. *J B J S* 64(9):1273-1281.
4. Gruca A in Tylman D (1995) Pathomechanics of lateral spine bends, Severus Publishing House, Warsaw. Seiten 167.
5. Heikkila E. (1984) Congenital dislocation of the hip in Finland. An epidemiologic analysis of 1035 cases, *Acta Orthop. Scandinavica* B.55(2): 125-129.
6. Hensinger RN (1979) Congenital dislocation of the hip. *Clin Symp* 31:270.
7. Howorth B (1977) The etiology of the congenital dislocation of the hip. *Clin Orthop* 29:164-179.
8. Karski T (1996) Contractures and growth disorders in the hip and pelvic area in the aetiology of the so-called idiopathic scoliosis-biomechanical considerations, *Orthopedic Practice* 32(3):155-160.
9. Karski T (2002) Etiology of the so-called “idiopathic scoliosis.” Biomechanical explanation of spine deformity. Two groups of development of scoliosis. New rehabilitation treatment, possibility of prophylactics. 91:37-46.
10. Karski T, Kalakucki J, Karski J (2006) "Syndrome of contractures" (according to Mau) with the abduction contracture of the right hip as causative factor for development of the so-called idiopathic scoliosis. *Stud Health Technol Inform* 123:34-9.
11. Karski T (2010) Explanation of biomechanical etiology of the so-called idiopathic scoliosis (1995-2007). New clinical and radiological classification” (*Locomotor System*). 17:26-42.
12. Karski T (2011) Biomechanical Etiology of The So-Called Idiopathic Scoliosis (1995-2007)-Connection with 279 “Syndrome of Contractures”- Fundamental Information for Paediatricians in Program of Early Prophylactics/280 *J US-China Med Sci* 8:78.
13. Karski T (2010) “Biomechanical factors in the etiology of idiopathic dinominated scoliosis. New 282 classification. New clinical tests and a new conservative treatment and prophylaxis,”*Questions of Physiotherapy* 39(2): 85-152.
14. Karski T (2010) “Biomechanical Etiology of the So-called Idiopathic Scoliosis (1995-2007). New Classification: Three Groups, Four Sub-types. Connection with “Syndrome of Contractures,” *Pan Arab J Orth Trauma* S2(1).
15. Karski T (2013) Biomechanical Etiology of the So-called Idiopathic Scoliosis (1995-2007). Three Groups and 288 Four Types in the New Classification, *J Nov Physiother* S2(1).
16. Karski J, Tomasz K (2013) So-Called Idiopathic Scoliosis. Diagnosis. Tests Examples of Children Incorrect 291 Treated. New Therapy by Stretching Exercises and Results, *J Nov Physiother* 3(3):9.

17. Karski T (2014) Biomechanical Aetiology of the So-Called Idiopathic Scoliosis. New Classification (1995-2007) in Connection with "Model of Hips Movements." Pages 12. *Glob J Med Res H: Orth and Musculoskeletal System* 14(3).
18. Karski T (2014) Biomechanical Etiology of the So-called Idiopathic Scoliosis (1995-2007)-Connection with "Syndrome of Contractures"-Fundamental Information for Pediatricians in Program of Early Prophylactics. *Surg Sci* 5:33-38.
19. Karski T, Karski J (2015) "Syndrome of Contractures and Deformities" according to Prof. Hans Mau as Primary Cause of Hip, Neck, Shank and Spine Deformities in Babies, Youth and Adults *Am Research J Med and Surg* 18(1):15-23.
20. Karski T, Jacek K (2015) Biomechanical etiology of the so-called Idiopathic Scoliosis (1995-2007). Causative role of "gait" and "permanent standing 'at ease' on the right leg." New classification. Principles of new therapy and causal prophylaxis. *Can Open Med Sci and Med J* 1(1):1-16
21. Karski J, Karski T (2016) "Imperfect hips" As a Problem at an Older Age. Early and Late Prophylactic Management before Arthrosis. *Jacobs J Phy and Exer* (2)1:15.
22. Karski J, Tomasz K, Jarosław P, Małgorzata K (2016) Deformations of the feet, knees, hips, pelvis in children and adults with minimal brain dysfunction. causes. treatment. Prophylaxis. *Locomotors System*. 23(2).
23. Karski T (2017) Physiotherapy-Correct, or Incorrect, Based on 'Wrong Principles of Treatment'. Example for Spine, Hip, Knee, Shank and Feet, *Orthop Res Online J* 1(1).
24. Karski T, Jacek K, Klaudia K, Katarzyna K, Honorata M (2018) Pediatric Prophylaxis Program of Motor System Deformations and Illnesses in Children. Problems of Spine, Hips, Knees and Feet, *EC PAEDIATRICALS*. 7.
25. Karski T, Jacek K, Katarzyna K, Klaudia K, Honorata M (2018) Prophylactic Rules for Newborns, Babies, Children and Adults in problems of Hip, Knee, Shank, Feet and Spine. *Orthop Res Online J* 2(1).
26. Karski T, Jacek K (2016) Low back pain-a neurological and orthopedic problem. Symptoms. Causes. Treatment. Back pain-neurology-orthopedic problems. Clinic, causes, therapy and prophylaxis. *Progress in Practical Neurology* 4:9-16.
27. Karski T (2018) Biomechanical Aetiology of the So-called Adolescent Idiopathic Scoliosis (AIS). Lublin Classification (1995-2007). Causative Influences Connected with "Gait" and "Standing 'at ease' on the Right Leg." *J Orthop and Bone Res*
28. Karski T (2019) Biomechanical Etiology of the So-Called Idiopathic Scoliosis, Connection with "Syndrome of Contractures and Deformities," Role of Gait and Standing 'At Ease' On the Right Leg in the Development of Spine Deformity, New Treatment, Causal Prophylactics. *Int J Orthop Res*.
29. Karski T (2019) Biomechanical Etiology of the So-called Idiopathic Scoliosis (Adolescent Idiopathic Scoliosis (AIS)). New Classification Rules of Therapy and Prophylaxis. *Nur and Hea Care J* 4(1):81-85.
30. Karski T, Karski J (2019) Problem of Hips. Children-Dysplasia. Adults-"Imperfect Hips" and Arthrosis. Methods of Prophylaxis and Therapy in Every Age, *J Inter Med* 2:7-25.
31. Lowe TG, Edgar M, Margulies JY, Miller NH, Raso VJ, et al. (2000) Etiology of idiopathic scoliosis: current trends in research. *J Bone Joint Surg Am* 82(A):1157-1168.
32. Malawski S (1992) Epidemiology of scoliosis, *Advances in Polish Spondyloorthopedia*.
33. Malawski S (1992) Own rules for the treatment of low-grade scoliosis, *Progress of Polish Spondyloorthopedia*.
34. Malawski S (1994) Own rules for the treatment of low-grade scoliosis in the light of contemporary views on the etiology and pathogenesis of scoliosis, *Chir Tools Movement and Orthop Half* 59(3):189-197.
35. Mau H (1979) On the etiopathogenesis of scoliosis, hip dysplasia and torticollis in infancy. *Magazine f. 294 Orthop* 5:601-605.
36. Mau H (1982) The Aetiopathogenesis of Scoliosis, *Library of the Orthopedist, Enke Verlag Stuttgart* 33(1):110.
37. Normelly H (1985) Asymmetric rib growth as an aetiological factor in idiopathic scoliosis in adolescent girls, 298 *Stockholm*. 1:103.
38. Rapala K in Tylman D (1995) Pathomechanics of lateral curvatures of the spine, *Severus Publishing House, Warsaw*. Seiten 167.
39. Stokes IAF (1999) Studies in Technology and Informatics, Research into Spinal Deformities 2, *IOS Press* 59(1):385.
40. Sevastik J, Diab K (1997) Studies in Technology and Informatics, Research into Spinal Deformities 1, *IOS 300 Press. Clinical Mechanics*. 15(5):387.
41. Tylman D (1995) Pathomechanics of lateral curvatures of the spine, *Publishing House Severus, Warsaw*, 167.
42. <http://www.ortopedia.karski.lublin.pl/> (active from 2006).