

---

# **Discussion on Back Pain Syndromes, Causes, Symptoms, Importance of Differential Diagnosis, Advises of Therapy**

**Karski Tomasz<sup>1\*</sup>, Karski Jacek<sup>2</sup>, Karska Klaudia<sup>3</sup> and Kulka Małgorzata<sup>4</sup>**

DOI: 10.9734/bpi/ctmamr/v12/6378D

---

## **ABSTRACT**

The back pain is a frequent problem of patients in orthopedics, neurology and other departments. In our opinion – the causes of the pain are connected with various illnesses or anatomical disorders of the spine such as hiperlordosis of lumbar spine, or scoliosis.

There are also other causes of back pain like spondylolysis, spodylolithesis, prolapsed nucleus pulpous, oncology symptoms but in the article we focus on the causes of special types of scoliosis and group of patients with “hiperlordosis of lumbar spine” as the causes of “back pain syndromes”. The back pain syndromes are mostly connected with the pathological changes in the anatomy of the spine – deformity of axis, changes of “intervertebral joints” and shortenings (contractures) of the soft tissues – ligaments, capsules, fascias, muscles of the spine. In our research we found that etiology of scoliosis is connected with biomechanical factors – “permanent standing ‘at ease’ on the right leg” and walking / gait, which is described in next chapters.

*Keywords: Back pain syndromes; symptoms; diagnosis; therapy.*

## **1. INFORMATION ABOUT ETIOLOGY OF THE SO-CALLED IDIOPATHIC SCOLIOSIS. [ADOLESCENT IDIOPATHIC SCOLIOSIS (AIS)] [1–45] (Figs. 1, 2, 3) AND ABOUT “BACK PAIN”**

In the years 1984 – 1995, in examination of many children - in 2020 the total number of patients has reached 2500, it was found that “idiopathic scoliosis” is connected with the asymmetrical movement of hips and next with function – permanent “standing ‘at ease’ on the right leg” and “gait”. Scoliosis is a three-dimensional deformity of vertebral column which is defined mostly based on lateral curvature of the spine [43, 44, 45]. The limitation of adduction of the right hip, or even abduction contracture of this joint 5 to 10 degree is one of the symptoms of “The Syndrome of Contractures and Deformities” [SofCD] according to Prof. Hans Mau from Tübingen, Germany (35, 36) and Lublin observations (T. Karski, J. Karski - 8 – 31). In the diagnosis, the checking of hips movement is crucial. The examination of hips movement should be in the straight position of these joints – and it is similar to the “standing position” or to the “stance phase in walking”. The etiology of scoliosis is strictly biomechanical and development of spine deformity is through function – “standing” and “gait” (Figs. 1, 2, 3). The standing on the right leg is permanent and once started at the age of two, lasts throughout the lifetime. So, the “cumulative time” of standing on the right leg is the cause of scoliosis and in adults the cause of “spine pain syndromes” (Figs. 4, 5a, 5b, 6a, 6b) and in many cases of “arthrosis of the right hip” [21,23,25,30].

---

<sup>1</sup>Vincent Pol University in Lublin, Poland.

<sup>2</sup>Pediatric Orthopedic and Rehabilitation Department, Medical University in Lublin, Poland.

<sup>3</sup>Radiology Department, Medical University in Lublin, Poland.

<sup>4</sup>Neurology Department, Medical University in Lublin, Poland.

\*Corresponding author: E-mail: tmkarski@gmail.com, t.karski@neostrada.pl;

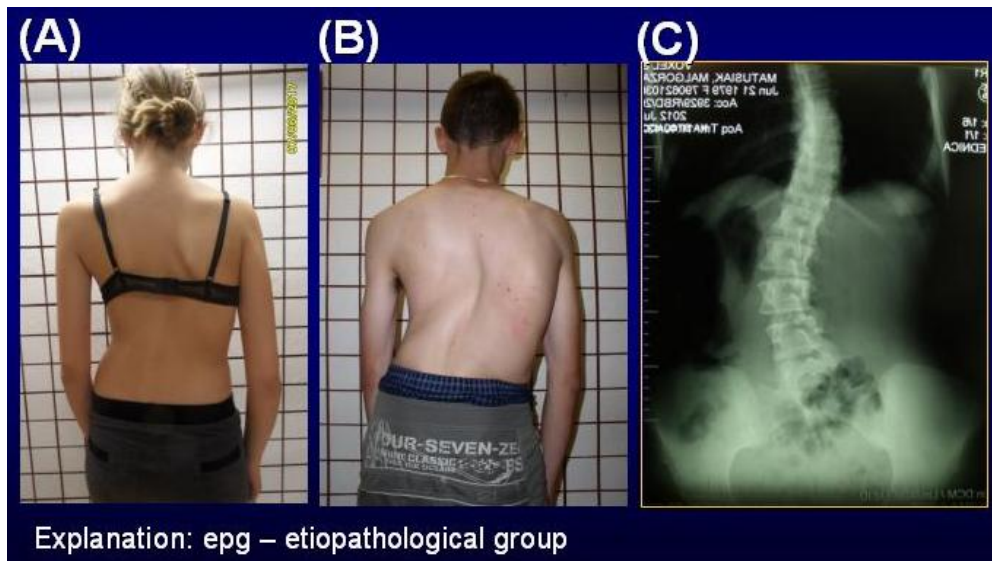


Fig. 1. Three groups and four types of scoliosis. In the picture three (3) cases (A) (B) (C) of “S” scoliosis in 1<sup>st</sup> epg. Causative influence: gait & standing. In case (B) – iatrogenic deformity, wrong exercises 5 years. In case (C) beginning of degenerate changes. If scoliosis is not proper treated in childhood – is the cause of deformity and back pain in adults

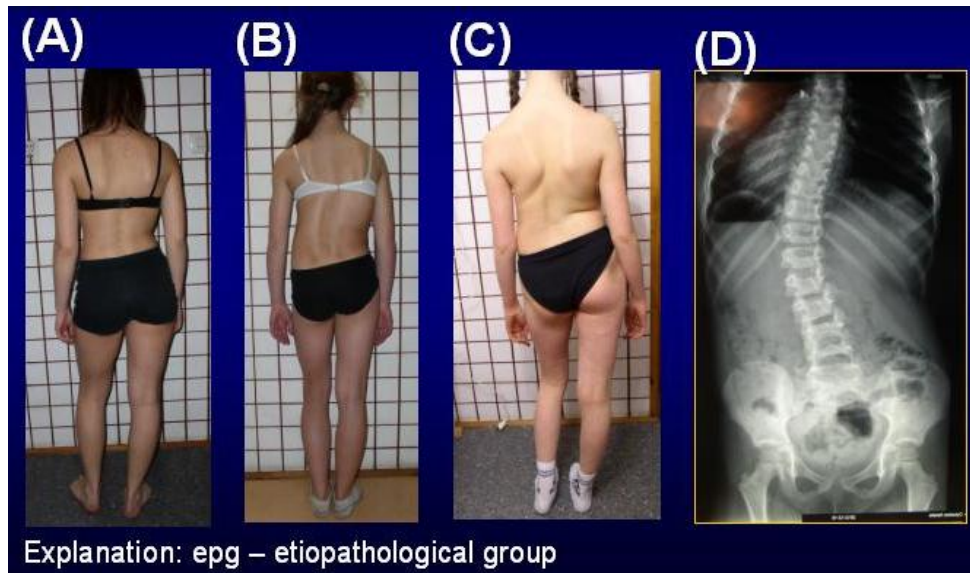


Fig. 2. Three groups and four types of scoliosis. In the picture 4 cases of “C” and “S” scoliosis in 2<sup>nd</sup>/ A / B epg. Causative influence: only standing ‘at ease’ on the right leg. In case (B) and (C) additionally laxity of joints and in result “S” scoliosis. If scoliosis is not proper treated in childhood – is the cause of back pain in adults

## 2. ADDITIONAL CAUSES IN DEVELOPMENT OF SCOLIOSIS IN CHILDREN AND BACK PAIN SYNDROMES IN ADULTS [19, 22–25]

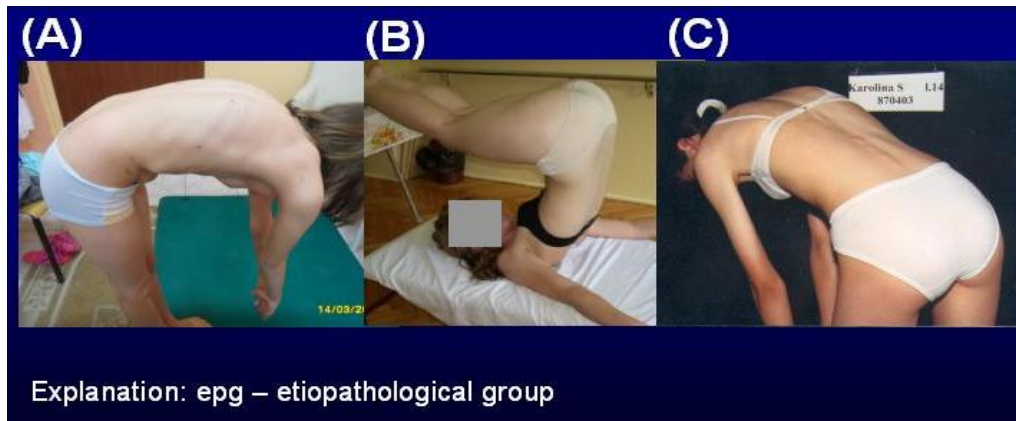
In many children or adults with scoliosis we can see “neurological symptoms” and there are typical for the Minimal Brain Dysfunctions (MBD). These neurological disorders are mostly caused by complicated or pathological pregnancies and problems in delivery. During examination of children and

adults suffering from scoliosis and back pain such anamnesis was constantly presented. The neurological disorders are:

a/ anterior tilt of pelvis and hiperlordosis of lumbar spine (Fig. 5a, 5b), because of flexion contracture of hips flexors. In such situation the stability between pelvis and spine is diminished – it enables an easy development of scoliosis and next back pain,

b/ extension contracture of the trunk's muscles as typical symptom of MBD – here we should remember that in “S” scoliosis in 1st epg group/type and in “I” scoliosis in 3rd epg group/type – the spine is stiff in “extension position” and this symptom is typical for all scoliosis patients (Fig. 6a, 6b). Stiffness of spine is one of many causes of back pains.

c/ laxity of joints - facilitates the development of scoliosis and is an important cause of back pain.



**Fig. 3. Three groups and four types of scoliosis. In the picture 3 cases of “I” scoliosis in 3rd epg. Causative influence: only gait. The properties of such type of deformity is stiffness, without or with small curves. If scoliosis is not proper treated in childhood – is the cause of back pain in adults. Stiffness of spine is frequently cause of spine pain but diagnosed by doctors rare**

### **3. NEW CLASSIFICATION OF SO-CALLED IDIOPATHIC SCOLIOSIS [8–30,42] (Figs. 1, 2, 3)**

The type of spine deformity is connected with “model of hips movement” and etiological factors – “gait” and “standing ‘at ease’ on the right leg”.

(1) Scoliosis 3D - “S” 1st etiopathological group (epg) - double curve. Stiff spine. Rib hump on the right side of the thorax. Connection with “gait” and permanent “standing ‘at ease’ on the right leg”. Mostly – rapid progression. This type of scoliosis “as example of the spine deformity” is described in orthopedic articles and in Internet.

(2a) Scoliosis 1D or 2D - “C” 2nd/A epg – one curve – lumbar left convex. Connected with permanent standing „at ease’ on the right leg. In many orthopedic articles this type of scoliosis is mostly described “as paresis / paretical scoliosis”.

(2b) Scoliosis 2D or 3D - “S” 2nd/B epg – two curves. Connection with permanent standing ‘at ease’ on the right leg and additionally with laxity of joints or / and previous, harmful exercises. In older people the standing on the right leg is the cause of degenerative scoliosis and heavy back pain syndrome (Fig. 4).

(3) Scoliosis 2D or 3D - “I” 3<sup>rd</sup> epg. Deformity has the form of a stiff spine. No curves or small ones. The only cause is gait. Clinical symptoms are “stiffness of the spine in children” and “pain syndromes in adults (Fig. 6a, 6b). Till 2004 this type of spine deformity was no described as “scoliosis”.

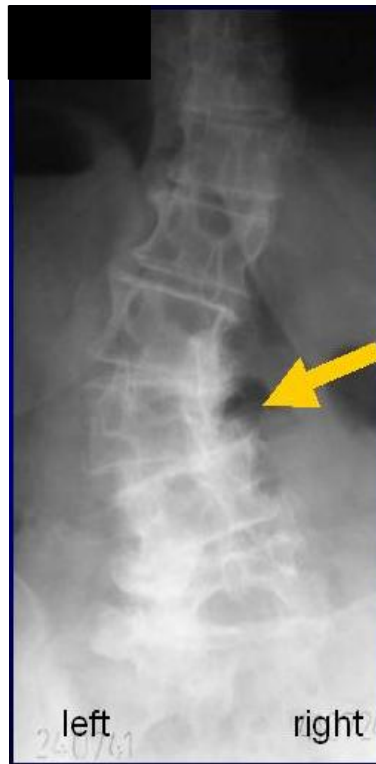

Fig. 4. Patient at the age of 62. Degenerative scoliosis „S” in 2nd/B epg as a result of standing ‘at ease’ on the right leg since the childhood. Permanent pain with radiation to the left leg. Therapy – standing only on the left leg or in a special position, resting and sleeping in embryo position. Massages. Chair extension (see Fig. 7)

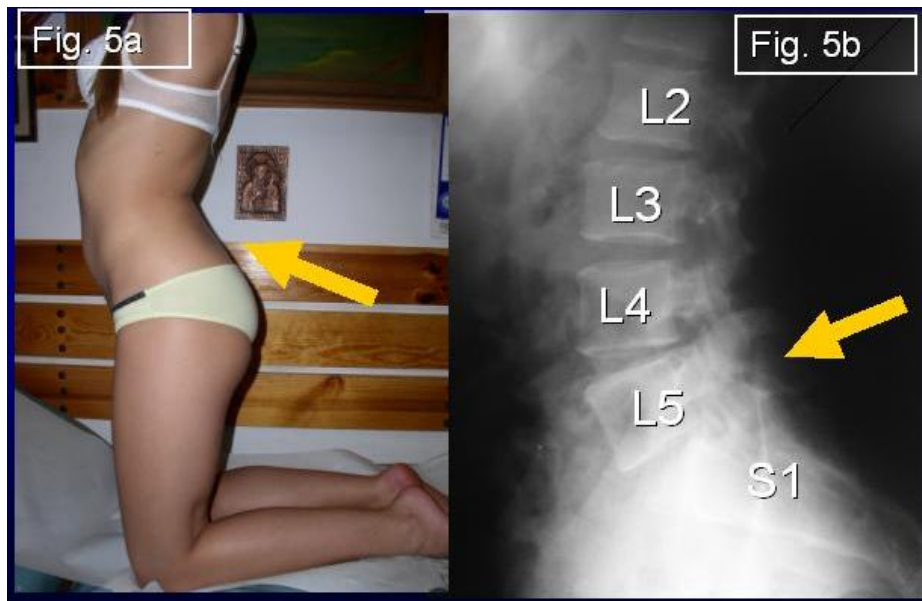
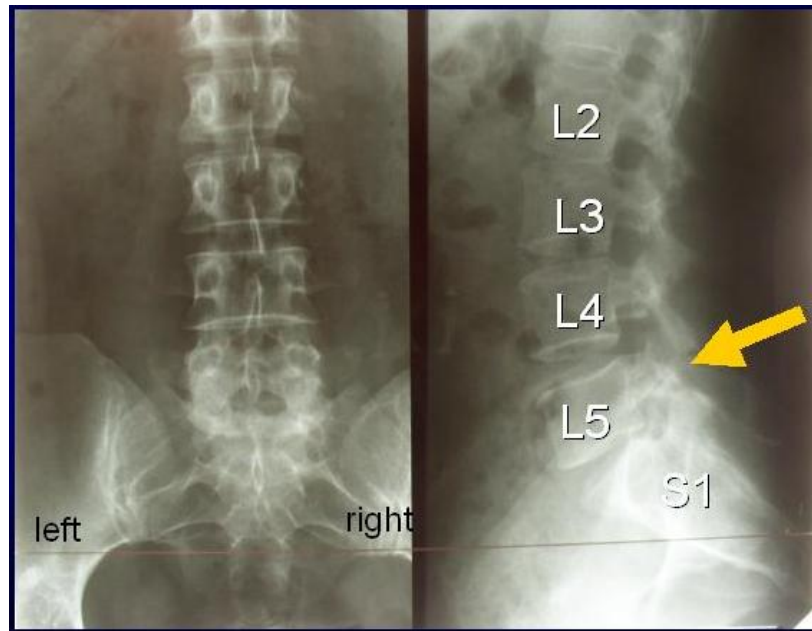


Fig. 5a, 5b. Girl, 13 years old. Example of anterior tilt of pelvis as a result of flexion contracture of the hips. Sacral bone in horizontal position, hiperlordosis of lumbar spine in clinical test & on X-ray. Deformity not treated in childhood – back pain in adult age



**Fig. 6a, 6b. Patient 60 years old. Example of scoliosis „I” in 3rd epg. Spine without curves but totally stiff. Oblique position of os sacrum. Deformity not treated in childhood. Now back pain in every day situation**

#### **4. PROBLEMS OF BACK PAIN IN CONTEXT OF SCOLIOSIS ON MATERIAL FROM 1984**

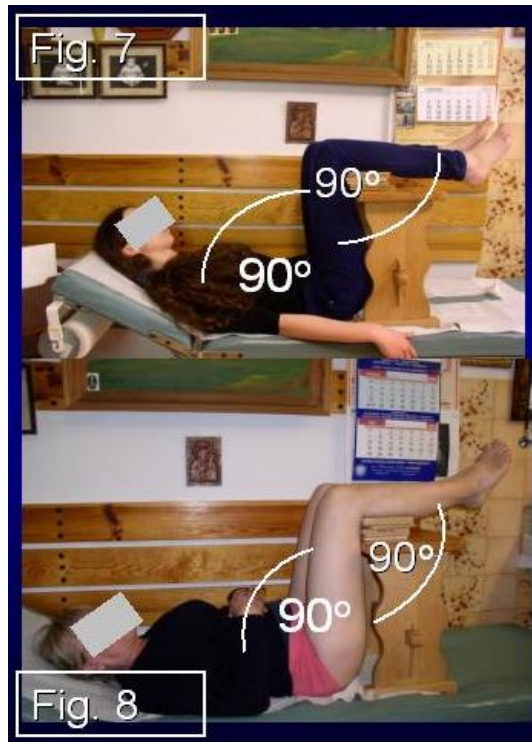
In our orthopedic experience – the problem of back pain is connected mostly with abnormalities of spine anatomy – therefore we describe in article two causes – hiperlordosis of lumbar spine and scoliosis “C” and “S” in 2nd etiopathological group and type (epg) in Lublin classification. Back pain syndrome can appear also if the spine is stiff. Such symptoms are typical for “I” scoliosis in 3rd epg group / type in new Lublin classification. Other causes are connected with the anatomical anomalies such as spondylolysis and spondylolisthesis. Since 1984 we have gathered a material containing 2500 patients, adults but also young people treated in Pediatric Orthopedic and Rehabilitation Department in Medical University in Lublin, Poland in years 1995 – 2009 (in these years Prof. T. Karski was the Head of the Department). In all orthopedic, neurology or another departments in many hospitals we should remember about necessity of differential diagnosis – the “back pain syndromes” can be connected with above described “orthopedic spine disorders” – scoliosis or only stiffness of spine and not as the symptoms of neurology or oncology diseases.

#### **5. PROPER THERAPY OF SCOLIOSIS AND BACK PAIN**

In the first plan – is very important to make proper, differential diagnosis to determinate the “the causes of illness and correct diagnosis”. In therapy of scoliosis in children - flexion stretching exercises for hips are very important – especially for right hip, for spine to cure the “contracture” – shortenings of soft tissues – muscles, fascias, tendons, capsules of the hips and spine joints. The aim of such therapy is – obtaining full, symmetrical movement of hips and spine what is essential for a correct development of spine. All these exercises are similar or the same as the ones in karate, taekwondo, aikido, kung fu or yoga. Here I would like to inform that flexion exercises in the treatment of scoliosis in Poland (1960 – 1970) were introduced by Prof. Stefan Malawski from Warsaw / Otwock (31 – 34 and with T. Karski personal discussions). Such early therapy in children we can see as “important prophylaxis program against “syndrome of back pain” in adults.

For patients with back pain we advise the resting and sleeping in embryo position, chair extension (Figs. 7, 8) to relieve the neuro-roots, exercises in warm water – especially in geothermal water and of

course, in serious cases, adequate analgesics. It is extremely important to avoid standing on the right leg by all neurological and other patients groups. In many cases standing on the left or in special "therapeutically position" in abduction 20 – 30 degree and in internal rotation 20 degree is very beneficial, at once diminishing the pain.



**Fig. 7. Patient 22 y. old. Anterior tilt of pelvis. Scoliosis "C" (2/A epg). Spondylolisthesis L5-S1. Pain with radiation to the left leg**

**Fig. 8. Patient 60 y. old. Scoliosis lumbar left convex – in new classification – "C" scoliosis 2nd epg. Back pain syndrome from 10 years**

*Treatment: Chair extension for the spine. The methods of therapy author (T. Karski) learned in Germany in 1968 in Orthopedic Department in Leipzig (in German: Perlsches Brett Behandlung). The extension therapy need long time be realized – many days or weeks. Additionally exercises in geothermal water and special method of standing – in abduction and internal rotation*

## 6. DISCUSSION TO THE PROBLEM OF SCOLIOSIS AND BACK PAIN

All old conceptions of etiology of "idiopathic scoliosis" [Literature 1, 2, 31, 37 - 41] were never conformed. The etiology of idiopathic scoliosis which deformity we called now "So-called Idiopathic Scoliosis" were described in 1995 – 2007 [T. Karski].

In our opinion the "back pain syndromes" occur in the following cases and in scoliosis cases particularly:

- 1/ Hiperlordosis of lumbar spine – because of "pressure syndromes" to nerve roots,
- 2/ Scoliosis in the new classification "C" and "S" in 2nd/A/B group – because of "presses on nerve roots" on concave site of curve or because of pulling on nerve root on convex side of spine,
- 3/ Stiffness of the spine – in scoliosis "I" in 3 rd group in the new classification, because of "lost of movement of spine",

4/ Spondylolisthesis,

5/ Back pain can be also as a symptom of various neurological or other illnesses.

Here I would like to explain that the cause of pain is situated in many places in the spine and surgery in such situation is not a proper method of therapy. According our opinion – the proper method of treatment is only physiotherapy. Here I would like to repeat our explanation – the cause of pain is situated in many levels of the spine. As surgery concentrates on one or two levels of the spine it cannot cure the spine pain as a whole. In our praxis we have observed – that physiotherapy is good in 30% of our patients, is excellent – in 20% and sufficient – in 50% of cases.

## **7. CONCLUSIONS**

1/ The back pain syndromes are mostly connected with the pathological changes in the anatomy of the spine – deformity of axis, changes of “intervertebral joints” and shortenings (contractures) of the soft tissues – ligaments, capsules, fascias, muscles of the spine.

2/ The changed axis and disorders in the anatomy of spine are caused mostly by So-called Idiopathic Scoliosis. There are three groups and four types of this deformity.

3/ There main causes of back pain are mostly:

- a/ Hiperlordosis of lumbar spine – in patients with primary MBD,
- b/ The “C” and “S” scoliosis in 2nd / A / B epg – in adults in form of degenerative spine deformity.
- c/ Stiffness of the spine in “I” 3 rd epg type of scoliosis – frequent spine pain cause but rare diagnosed till now.
- d/ Congenital or acquirer malformation of the spine like spondylolisthesis, congenital scoliosis, spine deformity in context of thorax deformity.

4/ All cases of “back pain” need the precise differential diagnosis to explain the causes of the illness.

5/ In prophylaxis of back pain in adults it is important to introduce to all children the rules of causal prophylaxis against scoliosis (see chapter above).

6/ In therapy of back pain – on the first plan is:

- a/ To avoid the standing ‘at ease’ on the right leg,
- b/ Rest and sleep in embryo position,
- c/ In heavy cases “chair extension” and in the “pain-free phase” of the illness - exercises in geothermal water.
- d/ Physiotherapy – regularly at home and in rehabilitations centers.

7/ Surgery in back pain syndromes is necessary only in very rare cases resistant to conservative treatment.

## **ACKNOWLEDGEMENT**

I would like to express my many thanks to Miss Honorata Menet for correction of the article.

## **COMPETING INTERESTS**

Authors have declared that no competing interests exist.

## **REFERENCES**

1. Burwell G, Dangerfield PH, Lowe T, Margulies J. Spine. Etiology of adolescent idiopathic scoliosis: Current trends and relevance to new treatment approaches. Hanley & Belfus, Inc, May 2000. Philadelphia. 2000;14(2):324.

2. Dangerfield PH, Dorgan JC, Scutt D, Gikas G, Taylor JF. Stature in Adolescent Idiopathic Scoliosis (AIS). 14 Meeting EPOS, Brussels, 5-April 1995, Papers and Abstracts. 1995;210.
3. Green NE, Griffin PP. Hip dysplasia associated with abduction contracture of the contralateral hip [1982]. *J.B.J.S.* 1982;268 63-A,1273-1281:269.
4. Gruca A. in Tylman D. *Patomechanika bocznych skrzywień kręgosłupa*, Wydawnictwo Severus, Warszawa, 1995, Seiten 167; 1995.
5. Heikkilä E. Congenital dislocation of the hip in Finland. An epidemiologic analysis of 1035 cases, *Acta Orthop. Scandinavica.* 1984;B.55:125-129.
6. Hensinger RN. Congenital dislocation of the hip. *Clinical Symp.* 1979;31:270.
7. Howorth B. The etiology of the congenital dislocation of the hip, *Clin. Orthop.* 1977;29:164-179, 271.
8. Karski T. Kontrakturen und wachstumstörungen im hüft- und beckenbereich in der ätiologie der sogenannten "idiopatischen Skoliosen" – biomechanische Überlegungen, *Orthopädische Praxis* 1996;32(3):155-160.
9. Karski T. Etiology of the so-called "idiopathic scoliosis". Biomechanical explanation of spine deformity. Two groups of development of scoliosis. New rehabilitation treatment. Possibility of prophylactics, *Studies in Technology and Informatics, Research into Spinal Deformities 4*, Vol. 91., IOS Press 2002, Amsterdam, Berlin, Oxford, Tokyo, Washington DC, 37-46; 2002.
10. Karski T, Kalakucki J, Karski J. Syndrome of contractures (according to Mau) with the abduction contracture of the right hip as causative factor for development of the so-called idiopathic scoliosis. *Stud Health Technol Inform.* 2006;123:34-9
11. Karski T. Explanation of biomechanical etiology of the so-called idiopathic scoliosis (1995 – 2007). New clinical and radiological classification "in" *Pohybove Ustroji* [Locomotor System] vol. 17, 2010, No.1 + 2, pages: 26 – 42 (Czech Republic - 2010); 2010.
12. Karski T. Biomechanical Etiology of The So-Called Idiopathic Scoliosis (1995 – 2007) – Connection with "Syndrome of Contractures" – Fundamental Information for Paediatricians in Program of Early Prophylactics / *Journal of US-China Medical Science, USA*, May 2011, Volume 8, No 78; 2011.
13. Karski Tomasz Factores biomechanicos en la etiologia de las escoliosis dinominadas idiopaticas. Nueva clasificacion. Nuevos test clinicos y nueavo tratamiento conservador y profilaxis. *Cuestiones de Fisioterapia*, Mayo- Agosto 2010, volumen 39, Numero 2, paginas 85 – 152 [Cuest. Fisioter. 2010, 39 (2); 144 – 152] / Spain [2010]; 2010.
14. Karski Tomasz. Biomechanical Etiology of the So-called Idiopathic Scoliosis (1995-2007). New Classification: Three Groups, Four Sub-types. Connection with „Syndrome of Contractures. *Pan Arab J. Orth. Trauma*, vol. (14), No 2, July 2010; 2010.
15. Karski Tomasz. Biomechanical Etiology of the So-called Idiopathic Scoliosis (1995 - 2007). Three Groups and Four Types in the New Classification, *Journal of Novel Physiotherapies*, OMICS Publishing Group, USA, 2013, S2, 6 pages; 2013.
16. Karski Jacek, Tomasz Karski. So-called idiopathic scoliosis. Diagnosis. Tests Examples of Children Incorrect Treated. New Therapy by Stretching Exercises and Results, *Journal of Novel Physiotherapies*, OMICS Publishing Group, USA, 2013, 3-2, 9 pages; 2013.
17. Karski Tomasz. Biomechanical aetiology of the so-called idiopathic scoliosis. New Classification (1995 – 2007) in Connection with "Model of Hips Movements". Pages 12. *Global Journal of Medical Research H: Orthopedic and Musculoskeletal System.* 2014;14(3):Version 1.0.
18. Karski Tomasz. Biomechanical etiology of the so-called idiopathic scoliosis (1995 – 2007) - Connection with „Syndrome of Contractures” – Fundamental Information for Pediatricians in Program of Early Prophylactics. *Surgical Science.* 2014;5:33-38 (USA).
19. Karski Tomasz, Karski Jacek. Syndrome of contractures and deformities according to Prof. Hans Mau as Primary Cause of Hip, Neck, Shank and Spine Deformities in Babies, Youth and Adults *American Research Journal of Medicine and Surgery*, 2015;1(2).
20. Karski Tomasz, Jacek Karski. Biomechanical etiology of the so-called Idiopathic Scoliosis (1995 – 2007). Causative role of "gait" and "permanent standing 'at ease' on the right leg". New classification. Principles of new therapy and causal prophylaxis. *Canadian Open Medical Science & Medicine Journal.* 2015;1(1):1–16.
21. Karski Jacek, Karski Tomasz. Imperfect hips As a Problem at an Older Age. Early and Late Prophylactic Management before Arthrosis. *Jacobs Journal of Physiotherapy and Exercises / USA / Texas.* 2016;1(2):015-7.



22. Karski Jacek, Tomasz Karski, Jarosław Pyrc, Małgorzata Kulka. Deformations of the feet, knees, hips, pelvis in children and adults with minimal brain dysfunction. causes. treatment. Prophylaxis. *Locomotors System*. 2016;23(2).
23. Karski Tomasz. Physiotherapy– Correct, or incorrect, based on ‘wrong principles of treatment’. Example for Spine, Hip, Knee, Shank and Feet, *Crimson Publishers, USA*; 2017. Published: August 21, 2017
24. Karski Tomasz, Jacek Karski, Klaudia Karska, Katarzyna Karska, Honorata Menet. Pediatric prophylaxis program of motor system deformations and illnesses in children. *Problems of Spine, Hips, Knees and Feet, EC PAEDIATRICS, Review Article 7.7*; 2018.
25. Karski Tomasz, Jacek Karski, Katarzyna Karska, Klaudia Karska, Honorata Menet. Prophylactic rules for newborns, babies, children and adults in problems of hip, knee, shank, feet and spine, *Online Journal CRIMSON PUBLISHERS, USA*; 2018. Published: March 12, 2018
26. Karski Tomasz, Jacek Karski. Bóle krzyża – problem neurologiczno - ortopedyczny. Objawy. Przyczyny. Leczenie. *Back pain – neurology-orthopedic problems. Clinic, causes, therapy and prophylaxis. Postępy Neurologii Praktycznej, Wydawnictwo Czelej. 4/2016, Str. 9 – 16*; 2016.
27. Karski Tomasz. Biomechanical aetiology of the so-called adolescent idiopathic scoliosis (AIS). Lublin Classification (1995-2007). Causative Influences Connected with “Gait” and “Standing ‘at ease’ on the Right Leg”, *Journal of Orthopaedics and Bone Research (USA), Scholarena*. 2018; 10.
28. Karski Tomasz. Biomechanical etiology of the so-called idiopathic scoliosis, connection with “syndrome of contractures and deformities. Role of Gait and Standing ‘At Ease’ On the Right Leg in the Development of Spine Deformity, New Treatment, Causal Prophylactics, *International Journal of Orthopaedics s Research, Review Article*. 2019;5.
29. Karski Tomasz. Biomechanical etiology of the so-called idiopathic scoliosis (Adolescent Idiopathic Scoliosis [AIS]). New Classification Rules of Therapy and Prophylaxis. *Nursing and Health Care Journal*. 2019;4(1):4.
30. Karski Tomasz, Karski Jacek. Problem of hips. Children – Dysplasia. Adults – “Imperfect Hips” and Arthrosis. Methods of Prophylaxis and Therapy in Every Age, *Journal of Internal Medicine, USA*. 2019;2:II / 2019;7-25.
31. Lowe TG, Edgar M, Margulies JY, Miller NH, Raso VJ, Reinker KA, et al. Etiology of idiopathic scoliosis: Current trends in research. *J. Bone Joint Surg. Am.* 2000;82-A:1157–1168.
32. Malawski Stefan. Epidemiologia skoliozy, *Postępy Polskiej Spondyloortopedii*. 1992;5:5.
33. Malawski Stefan. Własne zasady leczenia skolioz niskostopniowych, *Postępy Polskiej Spondyloortopedii*. 1992;2:2.
34. Malawski S. Własne zasady leczenia skolioz niskostopniowych w świetle współczesnych poglądów na etiologię i patogenezę powstawania skolioz, *Chir. Narz. Ruchu i Ortop. Pol.* 1994;59(3):189-197.
35. Mau H. Zur Ätiopathogenese von Skoliose, Hüftdysplasie und Schiefhals im Säuglingsalter. *Zeitschrift f. 294 Orthop.* 1979;5:601-5, 295.
36. Mau H. Die Ätiopathogenese der Skoliose, *Bücherei des Orthopäden, Band 33, Enke Verlag Stuttgart* 1982;1 – 296:110 297.
37. Normelly H. Asymmetric rib growth as an aetiological factor in idiopathic scoliosis in adolescent girls, *298 Stockholm*. 1985;1-103:299.
38. Rapała K. in Tylman D. *Patomechanika bocznych skrzywień kręgosłupa, Wydawnictwo Severus, Warszawa, Seiten*. 1995;167.
39. Stokes IAF. *Studies in technology and informatics, research into spinal deformities 2. IOS Press 1999, Amsterdam, Berlin, Oxford, Tokyo, Washington DC*. 1999;59:1-385.
40. Sevastik J, Diab K. *Studies in technology and informatics, research into spinal deformities 1, IOS 300 Press 1997, Amsterdam, Berlin, Oxford, Tokyo, Washington, DC* 1-509. 301. 1997;37.
41. Tylman D. *Patomechanika bocznych skrzywień kręgosłupa, Wydawnictwo Severus, Warszawa*. 1995;167.
42. Available:[www.ortopedia.karski.lublin.pl](http://www.ortopedia.karski.lublin.pl) [active from 2006]
43. Rogala EJ, Drummond DS, Gurr J. Scoliosis: Incidence and natural history. A prospective epidemiological study. *J Bone Joint Surg Am.* 1978;60:173–6.
44. Ma X, Zhao B, Lin QK. Investigation on scoliosis incidence among 24,130 school children. *Zhonghua Liu Xing Bing Xue Za Zhi*. 1995;16:109–10.

45. Karimi MT, Rabczuk T. Scoliosis conservative treatment: A review of literature. Journal of Craniovertebral Junction & Spine. 2018;9(1):3.

**Biography of author(s)**



**Karski Tomasz**

Vincent Pol University in Lublin, Poland.

**Research and Academic Experience:** 59 years in orthopaedics, rehabilitation, physiotherapy

**Research Area:** Children orthopaedics, adult orthopaedics, Hips. Knees. Spine. Foot. CP. MBD. SofCD.

**Number of Published papers:** More than 550

**Special Award (If any):** Hips – dysplasia. Lower extremities – axis. Spine – scoliosis. So-called Idiopathic Scoliosis. Describing of Aetiology (1995 – 2007). Classification. Therapy. Prophylaxis.

**Any other remarkable point(s):** Head in years 1995 – 2009 of Paediatric Orthopaedic and Rehabilitation Department, Medical University Lublin, Poland. From 2009 – retired in this State University. Professor Lecturer in Vincent Pol University (private) from 2009 – till now.



**Karski Jacek**

Pediatric Orthopedic and Rehabilitation Department, Medical University in Lublin, Poland.

**Research and Academic Experience:** 30 years in Paediatric Orthopaedics experience. Took part in numerous conferences, symposia's and meetings of Orthopaedic and rehabilitation too. Teacher in Medical University of Lublin in paediatric orthopaedic surgery field of polish and foreign medical students.

**Research Area:** Paediatric Orthopaedics: Ultrasound diagnostics, knee disorders, foot deformities and podology, cerebral palsy, spine problems, e.g. scoliosis, pediatric orthopaedic oncology and childrens traumatology.

**Number of Published papers:** 115

**Any other remarkable point(s):** Member of European Paediatric Orthopaedic Society, Polish Orthopaedic and Traumatology Society, Polish Paediatric Orthopaedic Society, Polish Podology Association, Polish Geothermal Association.

Active part in many Symposiums and Congresses including SICOT/SIROT Annual International Conference, Effort Congress, Epos Symposiums.

International co-organizer of Prague-Lublin-Sydney-St.Petersburg annual symposiums since 2004 till 2020.

Works closely with Slovak, Czech and Hungarian Orthopedic Societies which resulted in numerous co-operative Congresses and Meetings.

**Karska Klaudia**

Radiology Department, Medical University in Lublin, Poland.

She was born on 26<sup>th</sup> December 1985 In Lublin, Poland. In 2010 she completed graduation from Medical University in Lublin and in 2017 passed the European Board of Radiology exam – EDIR, and became a specialist in Radiology and Diagnostic Imaging. During the years 2011 – 2017 she worked in Interventional Radiology and Neuroradiology Department. From 2017 she is working in Paediatric Radiology Department of Medical University in Lublin, Poland.

---

© Copyright (2021): Author(s). The licensee is the publisher (Book Publisher International).

**DISCLAIMER**

This chapter is an extended version of the article published by the same author(s) in the following journal.  
Journal of Orthopedic Oncology, 6(1): 1-5, 2020.